

## Devices and methods to improve colonoscopy completion (with videos)

Prepared by: ASGE TECHNOLOGY COMMITTEE

Arvind J. Trindade, MD, David R. Lichtenstein, MD, FASGE, Harry R. Aslanian, MD, FASGE, Manoop S. Bhutani, MD, FASGE, Adam Goodman, MD, FASGE, Joshua Melson, MD, Udayakumar Navaneethan, MD, Rahul Pannala, MD, MPH, FASGE, Mansour A. Parsi, MD, FASGE, Amrita Sethi, MD, FASGE, Shelby Sullivan, MD, Nirav Thosani, MD, Guru Trikudanathan, MD, Rabindra R. Watson, MD, John T. Maple, DO, FASGE, Chair

This document was reviewed and approved by the governing board of the American Society for Gastrointestinal Endoscopy (ASGE).

*The American Society for Gastrointestinal Endoscopy (ASGE) Technology Committee provides reviews of existing, new, or emerging endoscopic technologies that have an impact on the practice of GI endoscopy. Evidence-based methodology is used, with a MEDLINE literature search to identify pertinent clinical studies on the topic and a MAUDE (U.S. Food and Drug Administration Center for Devices and Radiological Health) database search to identify the reported adverse events (AEs) of a given technology. Both are supplemented by accessing the “related articles” feature of PubMed and by scrutinizing pertinent references cited by the identified studies. Controlled clinical trials are emphasized, but in many cases data from randomized controlled trials (RCTs) are lacking. In such cases large case series, preliminary clinical studies, and expert opinions are used. Technical data are gathered from traditional and Web-based publications, proprietary publications, and informal communications with pertinent vendors.*

*Technology Status Evaluation Reports are drafted by 1 or 2 members of the ASGE Technology Committee, reviewed and edited by the committee as a whole, and approved by the Governing Board of the ASGE. When financial guidance is indicated, the most recent coding data and list prices at the time of publication are pro-*

*vided. For this review the MEDLINE database was searched through May 2017 for articles related to devices to improve colonoscopy completion using such relevant terms as colonoscopy, incomplete, abdominal binder, cap, wire, balloon enteroscopy, water irrigation, robotic colonoscopy, and colon capsule, among others. Technology Status Evaluation Reports are scientific reviews provided solely for educational and informational purposes. Technology Status Evaluation Reports are not rules and should not be construed as establishing a legal standard of care or as encouraging, advocating, requiring, or discouraging any particular treatment or payment for such treatment.*

### BACKGROUND

There are multiple diagnostic and therapeutic indications for colonoscopy. Quality guidelines recommend a cecal intubation rate of at least 90% for all colonoscopies and 95% for screening colonoscopies.<sup>1,2</sup> Incomplete colonoscopy (IC), defined as the inability to reach the cecum,<sup>3,4</sup> can result in missed colorectal cancer<sup>5</sup> and results in increased healthcare expenditure related to follow-up procedures (eg, repeat colonoscopy or CT colonography). Reported rates of IC range from 4% to 25% for both screening and nonscreening colonoscopy.<sup>6</sup> Risk factors for IC that relate to technical aspects of the colonoscopy include looping, a redundant colon, and sigmoid fixation/angulation, among others.<sup>4,6-10</sup>

Ideally, IC should be followed by a procedure that has both a high sensitivity for detecting mucosal pathology and offers therapeutic potential.<sup>6</sup> This is usually a repeat colonoscopy with a different colonoscope or the addition of a device.<sup>6,7,10</sup> Successful completion of colonoscopy is desirable because the yield of neoplasia on repeat colonoscopy after an IC can be as high as 53%.<sup>7</sup> In tertiary centers



**This video can be viewed directly from the GIE website or by using the QR code and your mobile device. Download a free QR code scanner by searching “QR Scanner” in your mobile device’s app store.**

Copyright © 2018 by the American Society for Gastrointestinal Endoscopy  
0016-5107/\$36.00  
<https://doi.org/10.1016/j.gie.2017.12.011>

the success rate of repeat colonoscopy after an IC can be as high as 95% to 97%,<sup>7,10,11</sup> but there is wide variability in successful cecal intubation in this setting, and success rates as low as 29% have been reported.<sup>5</sup> This document reviews devices and techniques that improve colonoscopy completion that can be applied during a challenging index colonoscopy or for patients returning after a previous IC. Although other diagnostic modalities such as CT colonography or video capsule colonoscopy are also viable options after IC, these technologies are beyond the scope of this document and are not discussed.

## TECHNOLOGY UNDER REVIEW

Endoscopic devices and techniques for colonoscopy completion usually provide benefit through 1 or more of the following mechanisms: prevention of looping, especially in redundant colons; safe advancement despite sigmoid fixation or angulation; pain reduction; or improved visualization. In this section we describe relevant technologies and their mechanism of action. Standard best practices such as loop reduction, patient position change, and manual abdominal pressure to aid colonoscopy completion should be attempted first before changing to an alternative scope or using additional devices. Additionally, beginning in the prone position may be helpful for colonoscopy completion in obese patients.<sup>12</sup> However, these routine maneuvers are not discussed in detail in this document.

### Endoscopes

Pediatric colonoscopes have greater shaft flexibility and a smaller insertion tube diameter (typically 11-12 mm) than adult colonoscopes,<sup>13</sup> making these instruments well suited for fixed and angulated colons.<sup>14</sup> Ultrathin colonoscopes and standard gastroscopes have an even smaller diameter (typically  $\approx$ 9-10 mm) and greater flexibility than pediatric colonoscopes.<sup>7,10,14,15</sup> Ultrathin colonoscopes and standard gastroscopes may allow for easier passage through angulations and narrow lumens,<sup>14,16</sup> although at the expense of a greater tendency to allow looping. A colonoscope with an 11.6-mm insertion tube diameter that is marketed for enhanced retroflexion (RetroView, EC-3490TLi; Pentax, Montvale, NJ, USA) features a shorter (9 cm) and slimmer (10.5 mm) bending portion that permits 210-degree retroflexion with a more compact turning radius than similar standard pediatric colonoscopes. Beyond enhanced retroflexion, this short turn radius colonoscope may allow for easier maneuverability around angulated and fixed colonic bends and has been evaluated for colonoscopy completion in patients with prior IC.<sup>17,18</sup>

Variable-stiffness colonoscopes (VSCs; models CF-HQ190 L/I, CF-H190 L/I, PCF-H190 L/I, PCF-PH190 L/I, CF-Q180AL/I, and PCF-Q180AL/I; Olympus America, Center

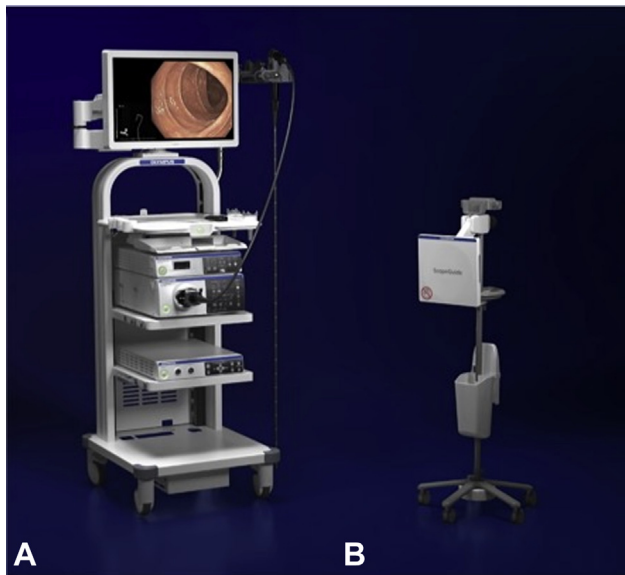
Valley, Pa) allow the endoscopist to control the stiffness of the scope. A dial near the junction of the insertion tube and the control handle<sup>19,20</sup> can be rotated manually to alter the stiffness of the scope. The dial connects to a central cable with a surrounding metal helical coil, and tension applied to the cable compresses and stiffens the helix and thus the colonoscope.<sup>20</sup> Loosening has the opposite effect, allowing the scope to become more floppy. The stiffening mechanism terminates a few centimeters from the distal tip.<sup>19-21</sup> A proposed method of using a VSC is to use the flexible mode in the sigmoid colon to navigate angulations, then stiffening the scope to reduce looping in the transverse and right side of the colon.<sup>21,22</sup>

### Balloon enteroscope-assisted colonoscopy

Both single-balloon and double-balloon enteroscopes have been used for completion of difficult colonoscopies; engagement of the overtube balloon with the colonic wall allows pleating of the colon with reduction maneuvers to facilitate further scope advancement. A single-balloon enteroscopy system (SIF-Q180 with overtube; Olympus America) uses a 200-cm enteroscope with a 9.2-mm outer diameter and a 140-degree field of view. The technique for single-balloon colonoscopy has been described in detail.<sup>23,24</sup> Various double-balloon instruments and techniques have also been used for difficult colonoscopy.<sup>25,26</sup> Traditionally, a standard-length double-balloon enteroscope (EN-450T5; Fujifilm, Tokyo, Japan) was used for double-balloon colonoscopy<sup>26</sup>; however, a shorter model (EC-450BI5; Fujifilm) that permits use of regular accessories has been cleared by the U.S. Food and Drug Administration and is available for use.<sup>27</sup> It has a 9.4-mm outer diameter, a working length of 152 cm, and a 140-degree field of view.

### Magnetic endoscopic imaging/fluoroscopy

Historically, fluoroscopy was sometimes used as an aid during difficult colonoscopies.<sup>28</sup> Although now used infrequently, fluoroscopy may assist with loop reduction during difficult cases if available.<sup>29</sup> Magnetic endoscopic imaging (MEI) is an alternative to fluoroscopy that provides real-time 3-dimensional views of the colonoscope configuration, allowing for identification of looping during colonoscopy.<sup>30-32</sup> Studies using MEI correlated via imaging that looping in the sigmoid colon causes significant pain that can alter colonoscopy outcomes.<sup>33</sup> An image of the colonoscope is generated through small electromagnetic transmitter coils within the insertion tube of the instrument. The transmitter coils are sensed by a mobile integrated unit/receiver dish containing a magnetic field generator, a central microprocessing unit, and large sensor coils.<sup>32</sup> The MEI processor is a compact unit that is typically positioned with the endoscope processing unit and light source. The receiver dish is positioned in close proximity to the patient's abdomen. The use of MEI is demonstrated in [Video 1](#) (available online at [www.giejournal.org](http://www.giejournal.org)).



**Figure 1.** Components of the magnetic endoscopic imaging system are seen. Note the scope configuration is seen in the lower left corner of the endoscopy image. (Image courtesy of and used with permission of Olympus America.)

[giejournal.org](http://giejournal.org)). Images showing the colonoscope configuration are displayed alongside the endoscopy view in a picture-in-picture format that is refreshed several times per second (Fig. 1). The MEI system is available from Olympus (ScopeGuide; Olympus Corporation, Tokyo, Japan). Pentax Medical (Tokyo, Japan) has developed an MEI system, called Scopepilot, that is currently not available in the United States.

### Through-the-scope balloon devices

The NaviAid ABC (SMART Medical System Ltd, Ra'anana, Israel) is a balloon catheter device intended to assist in navigating a difficult segment of the colon. It consists of a 60-mm latex-free polymer balloon at the distal end of a 7F, 250-cm catheter that is advanced through the instrument channel of the colonoscope (Fig. 2). During use the catheter is advanced beyond the challenging segment of the colon. The balloon is then inflated by attaching the catheter to an inflation system power supply (100-240 volts alternating current [VAC], 50-60 Hz). The balloon inflates to a pressure of  $60 \pm 10$  mbar, which corresponds to a diameter of up to 60 mm, and thus allows the balloon to serve as an anchor. Gentle insertion of the colonoscope and/or retraction of the balloon catheter allows the colonoscope to advance through the challenging segment toward the inflated balloon (Video 2, available online at [www.giejournal.org](http://www.giejournal.org)).

The Vizballoon (Visualization Balloons LLC, Roseland, NJ) is a urethane balloon catheter that is intended to facilitate colonoscope insertion without the use of gas insufflation. The balloon catheter requires a colonoscope



**Figure 2.** NaviAid ABC balloon catheter. (Image courtesy of and used with permission by SMART Medical System.)

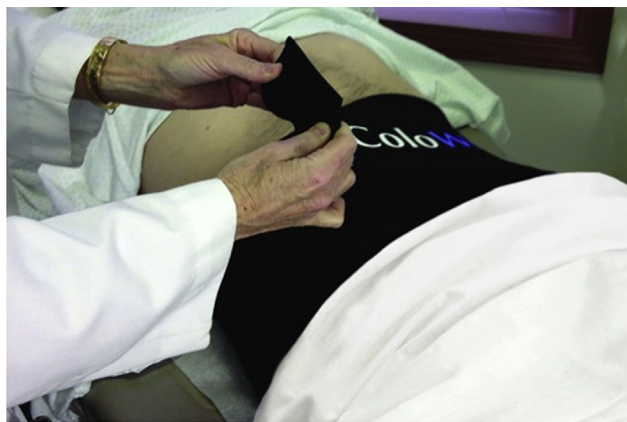

**Figure 3.** Vizballoon and associated Daisycuff. (Image courtesy of and used with permission by Visualization Balloons LLC.)

channel diameter of  $\geq 3.2$  mm and is used in conjunction with a short clear distal attachment (cap). After advancement of the catheter through the instrument channel, the balloon is inflated with saline solution to a diameter that approximates that of the colonoscope; the saline solution-filled balloon functions like a goggle in front of the colonoscope that allows for navigation through a nondistended colon (Fig. 3). The balloon also limits the “red-out” effect seen at acute angulations or from a spastic lumen, improving visibility. The manufacturer recommends the concurrent use of 2 elastic polymer pleating rings mounted on the shaft of the colonoscope insertion tube (Daisycuffs; Visualization Balloons LLC) (Fig. 3).

### Abdominal compression device

Manual compression of the abdomen by an endoscopy assistant may reduce looping and pain during a colonoscopy.<sup>33</sup> The pressure provided is variable in force and location.<sup>34</sup> An abdominal binder has been developed that



**Figure 4.** An example of an abdominal compression device (ColoWrap, LLC, Durham, NC) placed on a patient before colonoscopy. (Image courtesy of and used with permission of ColoWrap.)

encircles the patient's abdomen, applying constant pressure throughout the procedure (ColoWrap, LLC, Durham, NC) (Fig. 4).<sup>34,35</sup> ColoWrap is a single-use neoprene adjustable wrap that provides general lower abdominal compression, with a Velcro closure to allow for customized fitting. An additional support strap provides compression to the area overlying the sigmoid colon. The standard size ColoWrap is 100 cm × 25 cm. Other sizes are also available: small (90 cm × 20 cm), large (115 cm × 25 cm), and extra-large (130 cm × 25 cm).

### Transparent distal attachments (caps)

Transparent caps have been used in endoscopy to visualize areas at an angle or at a fold<sup>36</sup>; they are inexpensive and readily available.<sup>37</sup> A cap may be placed on the tip of the colonoscope before scope insertion (Fig. 5) and optionally may be secured by using adhesive tape.<sup>38</sup> Caps are classified as short (1-2 mm) medium (3-4 mm), or long (>4 mm) depending on the length of the cap beyond the distal tip of the scope.<sup>38</sup> Proposed mechanisms for the utility of caps in difficult colonoscopy include a better view of any sharp angulations of the sigmoid colon and facilitation of hooking of the tip of the colonoscope against a mucosal fold during loop reduction of the colon.<sup>39</sup> A variety of transparent caps of different sizes are available from several manufacturers.<sup>38</sup>

### Guidewire assistance

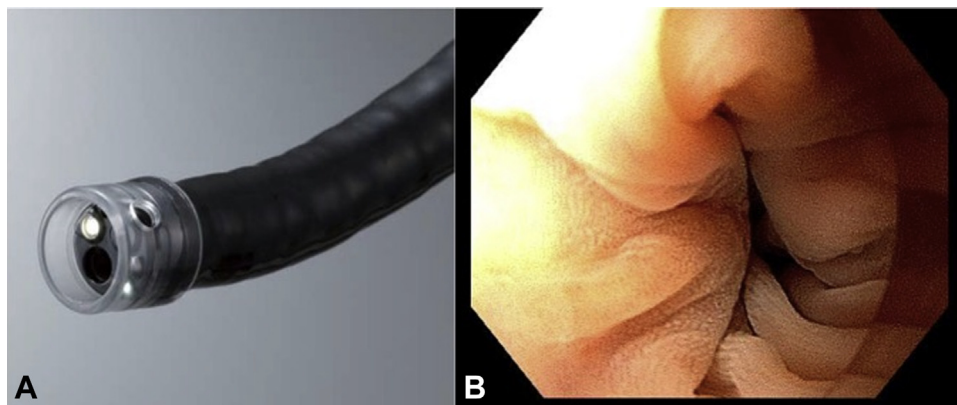
Guidewire-assisted colonoscopy can be considered when difficulty is encountered secondary to angulation, narrowing, or fixation of the sigmoid colon.<sup>11,40</sup> This technique is most commonly used when a pediatric colonoscope fails to negotiate the sigmoid colon and alternate instruments such as an ultrathin colonoscope or an enteroscope are unavailable. In this case a gastroscope may be used for sigmoid navigation and, if possible, complete

colonoscopy to the cecum. However, if the gastroscope traverses the difficult sigmoid segment but cecal intubation is not attained, a stiff guidewire of at least 360 cm length with a soft tip is advanced into the colonic lumen.<sup>41</sup> The gastroscope is withdrawn over the guidewire, and the back end of the wire is then inserted into the instrument channel at the tip of a pediatric colonoscope. In this manner the colonoscope is "back-loaded" onto the wire. Insertion of an ERCP catheter through the length of the instrument channel will direct the back-loaded guidewire out of the instrument hub in the scope handle; alternatively, a short length of tubing may be used for the same purpose. Tip deflection in the direction of the lumen while retracting small amounts of wire out of the patient facilitates advancement of the colonoscope through the sigmoid colon. Fluoroscopic assistance is typically not needed. The guidewire acts as a monorail and maintains the straightened configuration of the sigmoid colon resulting from prior passage of the gastroscope. Unless there is an actual stricture, successful advancement of the pediatric colonoscope is usually possible. Once the sigmoid colon has been traversed, the guidewire is withdrawn in its entirety, and the colonoscopy is completed using standard techniques.

### Stiffening device assistance

Placement of a device such as a biopsy forceps or dedicated stiffening wire in the instrument channel may increase the stiffness of the insertion tube, particularly when looping of the instrument prevents progression proximal to the splenic flexure.<sup>42</sup> The Zutron Stiffening Device (Zutron Medical, Kansas City, Mo) consists of a handle and rigid nitinol wire. The wire is tapered, more flexible, and rounded at the distal tip to avoid transmission of stiffness to the colonoscope bending section and to minimize the risk of instrument channel damage. Eight centimeters of heat shrink tubing just beyond the handle of each device improves the seal at the biopsy channel valve and minimizes leakage of insufflated gas. The colonoscope device is 170 cm long and available in 2 grades of stiffness: ZUTR141700 (standard, 1.4 mm diameter) and ZUTR161700 (firm, 1.6 mm diameter). A firm-stiffness enteroscope device (ZUTR162000, 1.6 mm diameter, 200 cm length) is also available. Ex vivo materials testing has indicated a 22% increase in shaft stiffness with use of the 1.4-mm wire and a 29% increase in stiffness with the 1.6-mm wires per the manufacturer. All Zutron stiffening devices are reusable.

The use of external stiffening devices such as overtubes to minimize looping has been reported.<sup>43,44</sup> Overtubes are typically preloaded onto the insertion tube of the colonoscope and advanced over the scope after the sigmoid colon has been reached.<sup>44</sup> Further advancement of the colonoscope may then be achieved with little or no sigmoid looping.



**Figure 5.** **A**, An example of a transparent cap fitted on a colonoscope. (Image courtesy of and used with permission of Olympus America.) **B**, Example of a cap used during a previously failed colonoscopy because of an acute angulation. The cap is able to visualize the angulation to help traverse it to complete the colonoscopy.

### Water-assisted techniques

Water-assisted colonoscopy (WAC) refers to filling the colon with water to facilitate advancement of the colonoscope to the cecum. Infusion of water straightens the sigmoid colon and reduces loop formation, reduces spasm, and avoids air-induced distention and elongation of the colon.<sup>45-51</sup> Consequently, a shorter distance may need to be traversed by the colonoscope to achieve cecal intubation, and the procedure may require fewer attendant maneuvers to manage looping, such as position change or abdominal pressure.<sup>45</sup> Two variations of WAC include water immersion and water exchange, which are described in detail in a prior ASGE Technology Assessment entitled “Methods of luminal distention for colonoscopy.”<sup>52</sup>

### OUTCOMES DATA AND COMPARATIVE EFFECTIVENESS

#### Endoscopes

In a retrospective evaluation of a prospectively maintained database, outcomes in 520 patients referred to a single expert endoscopist after IC were reported.<sup>7</sup> In these patients a general approach was taken whereby an adult colonoscope was selected if the mechanism for prior failure was looping/redundancy, and a pediatric colonoscope was selected if the issue was sigmoid angulation, fixation, or narrowing.<sup>7</sup> The authors reported a 97% completion rate with this strategy.<sup>7</sup> In the remaining cases other scopes were used to complete the exam including gastroscopes (7%) and enteroscopes (5%). A different retrospective series from a tertiary care hospital evaluated 100 patients with prior IC. In this series complete colonoscopy was achieved in 83% of patients using an adult colonoscope (35%), pediatric colonoscope (43%), or gastroscope (23%)<sup>10</sup>; in 15% of the cases more than 1 type of scope was used. A

retrospective study evaluated the short turn radius colonoscope in 30 patients with prior IC at a tertiary academic center.<sup>16</sup> Nineteen patients (63%) had prior abdominal/pelvic surgery, the site of failure was the sigmoid colon in 23 (77%), and all 30 were described as having fixation/immobility of the colon. Colonoscopy to the cecum was possible in 27 of 30 patients (90%) using the short turn radius colonoscope, with no AEs observed.

Multiple RCTs have been performed evaluating VSCs for difficult colonoscopy. A meta-analysis of 8 RCTs totaling 2033 patients compared VSC with standard colonoscopy (SC).<sup>53</sup> The studies included varied in patient population, from unselected outpatients to patients with difficult colonoscopies or IC. Cecal intubation rates were higher with the use of VSC (relative risk, 1.03; 95% confidence interval [CI], 1.01-1.06). Another meta-analysis of 7 RCTs reported a similar benefit in colonoscopy completion with VSC (odds ratio [OR], 2.08; 95% CI, 1.29-3.36).<sup>19</sup>

A meta-analysis of 2191 patients across 7 studies (6 RCTs, 1 observation cohort study) compared cecal intubation rates using standard adult colonoscopes versus ultrathin colonoscopes. Colonoscopy with an ultrathin scope was superior to SC for cecal intubation rate (98.4% vs 96.4%; OR, 2.30; 95% CI, 1.31 - 4.03).<sup>15</sup> Most patients in these studies had screening or polyp surveillance as indications and were not an IC or difficult colonoscopy cohort.

Gastroscopes have been reported to permit unsedated colonoscopy in patients with a low body mass index; despite a shorter length (around 100 cm), high rates of cecal intubation have been reported using a gastroscope when the patient’s body mass index is <22 kg/m<sup>2</sup>.<sup>10,54</sup> Gastroscopes also frequently allow safe retroflexion in many colon segments, including the left side of the colon, an area typically associated with difficult colonoscope retroflexion.<sup>54</sup> In a retrospective single-center study of completion colonoscopy after IC, gastroscopes were used for successful completion in 7% of patients.<sup>7</sup>

## Balloon enteroscope–assisted colonoscopy

A meta-analysis of 14 studies comprising 667 patients across 18 centers evaluated the efficacy of balloon enteroscope–assisted colonoscopy after IC.<sup>55</sup> Fluoroscopy was used in 11 studies. In this analysis the pooled cecal intubation rate was 97%, and the mean insertion time was 21 minutes. Similarly, a systematic review of 16 double-balloon enteroscope–assisted colonoscopy studies that evaluated 621 patients with prior IC reported a pooled cecal intubation rate of 95% (range, 87.5%-100%;  $P = .0006$ ).<sup>56</sup> In 2 prospective cohort studies of consecutive patients referred after IC, single-balloon enteroscope–assisted colonoscopy was successful in attaining cecal intubation in 96% to 98%.<sup>57</sup>

In an RCT comparing single-balloon enteroscope–assisted colonoscopy with SC in 30 patients with prior IC, single-balloon colonoscopy was superior to SC (93% vs 50%,  $P = .016$ ) for achieving cecal intubation.<sup>23</sup> Studies comparing single-balloon and double-balloon enteroscope–assisted colonoscopy in patients with prior IC showed similar efficacy in cecal intubation.<sup>58,59</sup> A Japanese multicenter prospective study of 110 patients evaluated the safety and efficacy of a short double-balloon enteroscope (EC-450BI5; Fujifilm) in patients with previous IC.<sup>27,60</sup> Cecal intubation was achieved in all patients.

## Magnetic endoscopic imaging

A meta-analysis of 13 RCTs compared MEI with SC for unselected patients undergoing elective procedures.<sup>61</sup> MEI was associated with a lower risk of failed cecal intubation (risk difference, 4%; 95% CI, 0%-7%;  $P = .03$ ) and a shorter cecal intubation time (mean difference, .58 minutes; 95% CI, .28-.88;  $P < .001$ ). Another meta-analysis of 8 RCTs comparing colonoscopy using MEI versus SC similarly reported a higher cecal intubation rate with MEI as compared with SC (95.2% vs 91.2%; OR, 1.92; 95% CI, 1.13-3.27).<sup>62</sup> In a subgroup analysis this effect was only statistically significant for endoscopists with less experience, defined as fewer than 6 years of experience performing colonoscopy or fewer than 200 lifetime colonoscopies. An RCT of 133 consecutive patients undergoing colonoscopy performed by both trainees and experienced endoscopists indicated that use of MEI was associated with several benefits, including higher procedure completion rates among trainees, shorter cecal intubation times in both groups (15% reduction in time for experienced endoscopists vs 30% for trainees;  $P \leq .05$  for both groups), fewer attempts at straightening the scope, shorter duration of looping in both groups, more effective application of abdominal pressure in both groups, and higher cecal intubation rates for technically difficult cases among experienced endoscopists.<sup>30</sup>

## Through-the-scope balloon devices

There are limited data available on through-the-scope balloon devices, with all evaluations to date published

only in abstract form. In a pilot study of 9 challenging colonoscopy patients, use of the NaviAid ABC balloon was associated with successful cecal intubation in all 9 patients.<sup>63</sup> In a study of 103 consecutive patients with documented previous difficult colonoscopy (including 16 with IC), use of the Vizballoon during insertion was associated with a 100% cecal intubation rate.<sup>64</sup> In another single-center evaluation of the Vizballoon in 86 patients undergoing elective colonoscopy, per protocol use of the Vizballoon was associated with a cecal intubation rate of 83.7%.<sup>65</sup> The Vizballoon was considered helpful in 82.5% of cases and a hindrance in 17.5% of cases.<sup>65</sup> The Vizballoon was safe and well tolerated in all patients.

## Abdominal binders

The use of an abdominal binder was evaluated in 2 RCTs on unselected patients undergoing colonoscopy (not with prior IC).<sup>34,35</sup> Neither study demonstrated a difference in cecal intubation rates or cecal intubation time with use of the binder as compared with a sham device or no device. Abdominal binders have not yet been evaluated in patients with prior IC.

## Transparent caps

A Cochrane review summarized 12 RCTs with a total of 5932 total patients who underwent colonoscopy with a cap versus SC.<sup>37</sup> Although the individual RCTs reported conflicting results, on meta-analysis there was no significant difference in cecal intubation rates between the 2 groups (OR, 1.36; 95% CI, .95-1.93). Two other meta-analyses provided conflicting results, with 1 finding a higher cecal intubation rate with cap colonoscopy<sup>66</sup> and another finding no difference in cecal intubation rates between cap colonoscopy and SC.<sup>67</sup> It is important to note that in all these analyses, none of the individual studies was focused on a difficult colonoscopy or IC cohort.

A prospective single-center study evaluated 52 patients in whom the sigmoid colon could not be traversed during SC.<sup>68</sup> Colonoscopy was completed at the same session in 46 of 52 patients (89%) with a gastroscope and a transparent cap. In a prospective single-center study of 139 patients with a prior IC because of a difficult sigmoid colon, patients were randomized to cap colonoscopy with an adult colonoscope or cap colonoscopy using a gastroscope.<sup>39</sup> The cecal intubation rate was higher in the gastroscope group than in the adult colonoscope group (94% vs 71%,  $P = .001$ ). In a crossover arm, cap-assisted colonoscopy with a gastroscope was successful in 90% of patients who failed cap-assisted colonoscopy using an adult colonoscope.

## Water-assisted colonoscopy

Although WAC techniques have been associated with higher cecal intubation rates than standard approaches for unsedated or minimally sedated patients,<sup>50,69,70</sup> this

advantage has not been demonstrated for patients undergoing colonoscopy with moderate or deep sedation.<sup>45,51</sup> A trial of 110 patients with anticipated difficult colonoscopies (women with prior abdominal or pelvic surgery, many also with a low body mass index) randomized participants to either air insufflation or water exchange during unседated colonoscopy.<sup>70</sup> The WAC group had a higher cecal intubation rate than the air insufflation group (92.7% vs 76.4%,  $P = .03$ ). In a single-operator study 345 consecutive patients referred for a previous IC underwent colonoscopy with sedation, including 178 in whom WAC techniques were used and 167 in whom air insufflation was used. In this cohort there was no difference in cecal intubation rates between WAC and SC (95.5% vs 97%,  $P = .58$ ).<sup>45</sup> However, among the subset of 148 patients with redundant colons as the primary cause for the prior IC, WAC decreased the need for external straightening devices (7% vs 37%,  $P < .0001$ ) and position change maneuvers (5% vs 22%,  $P = .01$ ).

### Guidewire assistance

There are limited data on the utility of wire-assisted techniques for completion of difficult colonoscopies. In a study of 520 IC patients referred for repeat colonoscopy, the guidewire exchange technique was successfully used in 19 patients (3.8%).<sup>7</sup> Any failures or the overall success rate using this guidewire technique was not reported. This technique is likely used less frequently than in the past because of the development of ultrathin colonoscopes and enteroscopy systems.

### Stiffening device assistance

A single-center randomized trial of 112 unselected patients undergoing colonoscopy failed to demonstrate an improvement in cecal intubation rates with routine use of a stiffening wire.<sup>42</sup> However, an improvement in cecal intubation rate with use of the stiffening wire (from 81.1% to 97.3%,  $P = .03$ ) was observed in a subgroup of patients in whom initial failure to progress occurred after colonoscope advancement proximal to the splenic flexure.

### SAFETY

Reported AEs at repeat colonoscopy after an IC are very low despite these examinations being challenging. There were no reported perforations from 3 retrospective series (710 total patients with prior IC) that used an adult colonoscope, pediatric colonoscope, adult gastroscope, or enteroscope for repeat colonoscopy.<sup>6,7,10</sup> The only reported AE from these series was 1 postpolypectomy bleed. It should be noted that most data on repeat colonoscopy after IC come from tertiary care centers where the procedures are performed by expert endoscopists.

Available data indicate that the rate of AEs using VSCs or ultrathin colonoscopes is very low and unlikely to be different from standard instruments. No AEs have been reported when MEI technology is used during colonoscopy.<sup>33,62,71</sup> Reports on double-balloon enteroscopy-assisted colonoscopy have not observed AEs in the diagnostic phase of the exam; minor self-limited bleeding has been reported with polypectomy during double-balloon enteroscopy-assisted colonoscopy.<sup>25,56</sup> Single-balloon enteroscopy-assisted colonoscopy also appears to be safe, with only minor mucosal tears and bleeding reported.<sup>59</sup> AEs have not been reported with through-the-scope balloon devices.

Studies of abdominal binders have reported no difference in the rate of AEs in the control and binder groups.<sup>34,35</sup> Reported AEs appear to relate to the colonoscopy itself and not the abdominal binder. Use of a transparent cap also appears to be safe; no AEs were reported in 3 meta-analyses.<sup>37,66,72</sup>

Hypothermia is a theoretical concern with WAC but has not been reported or formally evaluated in clinical studies. Hypothermia can be avoided with the use of warm water that approximates body temperature. With up to 2 L of water infused during WAC, intravascular volume and metabolic derangements are also of theoretical concern. However, limited studies have not demonstrated alterations in serum electrolytes (sodium, potassium, chloride, or bicarbonate levels), vital signs, or cardiac rhythm.<sup>73,74</sup>

### EASE OF USE

Repeat colonoscopy after an IC can be challenging and may require the use of different endoscopes and equipment; as such, adequate time should be allotted for these predictably difficult procedures.<sup>6,7,10</sup> When possible, it is helpful to understand the reason(s) for an IC, because this will guide subsequent attempts. Balloon colonoscopy requires a similar skill set to balloon enteroscopy; prior experience with these systems is appropriate to enhance the likelihood of a safe and successful exam.

Instilling water into the colonic lumen for WAC brings uncleaned stool into suspension, and the resulting turbidity interferes with luminal visualization. Suctioning turbid water and replacing it with clean water overcomes this issue but at the expense of added time. Practically, 1 to 2 L of warm water (tap or sterile) must be prepared before WAC. Use of an auxiliary peristaltic flushing pump is simpler and faster than manual water instillation with 60-mL syringes.

The technique of WAC is not difficult to learn, but no learning curve or ease of use data has been reported in a difficult colonoscopy population. Rather, available learning curve data for WAC have focused on maintaining strict WAC technique in a lightly sedated screening colonoscopy patient cohort.<sup>75</sup>

**TABLE 1. List price of devices to assist in difficult or incomplete colonoscopy**

Product	List Price (USD)	Comment
MEI ScopeGuide, model number UPD-3, Olympus America	21,300	
Single-balloon overtube, model number ST-SB1, Olympus America	299	Single use
Double-balloon overtube, Fujifilm	226	Single use
Distal cap for pediatric and adult colonoscope, model number D-201-12704/D-201-14304, Olympus America	38	Single use
NaviAid Spark Inflator, item 28-016, SMART Medical System Ltd.	7800	
NaviAid AB catheter, item 24-025, SMART Medical System Ltd.	227	Single use
DaisyCuff, Visualization Balloons LLC	15	Single use
Vizballoon, Visualization Balloons LLC	65	Single use
ColoWrap, ColoWrap, LLC	150	Single use, variations in price depending on size
Zutron Stiffening Device, Zutron Medical	895	Multiple use

## FINANCIAL CONSIDERATIONS

List prices for devices that assist in difficult colonoscopy or IC are reported in Table 1. Standard Current Procedural Terminology colonoscopy codes are used for repeat colonoscopy after an IC, even if specialty instruments such as balloon enteroscopes are used. An increased procedural services modifier code (modifier code 22) may be used when billing for a colonoscopy that requires significant time and/or effort to complete. Documentation must be provided to support the claim of why the procedure was beyond the usual range of difficulty. Some payers require that at least a 25% additional effort than usual be required to bill this modifier. Modifier 22 is for physician reporting only and not for facilities. Claims submitted with this modifier are open to a full medical review.

## AREAS FOR FUTURE RESEARCH

Colonoscopy completion is dependent on a complex set of variables that relate to the patient, the endoscopist, and the equipment used. Although algorithmic approaches for patients with prior IC have been suggested, validation in a prospective cohort would be useful. Comparative and cost-effectiveness analyses of competing strategies (eg, repeat colonoscopy, CT colonography, capsule colonoscopy) after IC are needed. Data on patients with prior IC largely arise from academic centers; community-based data would improve the generalizability of findings regarding useful techniques and devices. Most studies of repeat colonoscopy after IC compare a device or specialty scope with SC. Limited data compare 2 or more nonstandard devices, scopes, or techniques for difficult colonoscopy. There are no studies evaluating MEI, abdominal binders, or transparent caps in an IC cohort. Finally, robotic or computer-assisted colonoscopy systems are available and in use outside of the United States.<sup>76-79</sup> Pilot studies have shown

that these devices are feasible, safe, reduce looping, and allow for minimal sedation.<sup>76-79</sup> These devices appear to be promising for individuals with difficult colonoscopy or previous IC but should be specifically studied in these patient cohorts.

## SUMMARY

Colonoscopy is the most common GI endoscopic procedure, and most of these examinations are completed without difficulty. However, a subset of these procedures prove to be technically challenging and may defy safe completion using standard colonoscopes and techniques. Familiarity with alternative methods, scopes, and devices will help to guide the optimal management of these patients.

## DISCLOSURE

*The following authors disclosed financial relationships relevant to this publication: U. Navaneethan: Consultant for Abbvie, Takeda, and Janssen. R. Pannala: Consultant for Boston Scientific; research funding recipient from Fujifilm. M. A. Parsi, R. R. Watson: Consultant for Boston Scientific. H. R. Aslanian, A. Sethi: Consultant for Olympus and Boston Scientific. N. Thosani: Speaker and consultant for Boston Scientific and Medtronic; consultant for Mederi Inc.; speaker for Abbvie. A. Goodman: Consultant for Invendo Medical. All other authors disclosed no financial relationships relevant to this publication.*

*Abbreviations: AE, adverse events; ASGE, American Society for Gastrointestinal Endoscopy; CI, confidence interval; IC, incomplete colonoscopy; MEI, magnetic endoscopic imaging; OR, odds ratio; RCT, randomized controlled trial; SC, standard colonoscopy; VSC, variable-stiffness colonoscope; WAC, water-assisted colonoscopy.*



## REFERENCES

1. Rex DK, Schoenfeld PS, Cohen J, et al. Quality indicators for colonoscopy. *Gastrointest Endosc* 2015;81:31-53.
2. Rex DK, Bond JH, Winawer S, et al. Quality in the technical performance of colonoscopy and the continuous quality improvement process for colonoscopy: recommendations of the U.S. Multi-Society Task Force on Colorectal Cancer. *Am J Gastroenterol* 2002;97:1296-308.
3. Hanson ME, Pickhardt PJ, Kim DH, et al. Anatomic factors predictive of incomplete colonoscopy based on findings at CT colonography. *Am J Roentgenol* 2007;189:774-9.
4. Shah HA, Paszat LF, Saskin R, et al. Factors associated with incomplete colonoscopy: a population-based study. *Gastroenterology* 2007;132:2297-303.
5. Rizek R, Paszat LF, Stukel TA, et al. Rates of complete colonic evaluation after incomplete colonoscopy and their associated factors: a population-based study. *Med Care* 2009;47:48-52.
6. Brahmania M, Park J, Svarta S, et al. Incomplete colonoscopy: maximizing completion rates of gastroenterologists. *Can J Gastroenterol* 2012;26:589-92.
7. Bick BL, Vemulapalli KC, Rex DK. Regional center for complex colonoscopy: yield of neoplasia in patients with prior incomplete colonoscopy. *Gastrointest Endosc* 2016;83:1239-44.
8. Sanaka MR, Shah N, Mullen KD, et al. Afternoon colonoscopies have higher failure rates than morning colonoscopies. *Am J Gastroenterol* 2006;101:2726-30.
9. Anderson JC, Gonzalez JD, Messina CR, et al. Factors that predict incomplete colonoscopy: thinner is not always better. *Am J Gastroenterol* 2000;95:2784-7.
10. Gawron AJ, Veerappan A, Keswani RN. High success rate of repeat colonoscopy with standard endoscopes in patients referred for prior incomplete colonoscopy. *BMC Gastroenterol* 2014;14:56.
11. Rex DK, Chen SC, Overhiser AJ. Colonoscopy technique in consecutive patients referred for prior incomplete colonoscopy. *Clin Gastroenterol Hepatol* 2007;5:879-83.
12. Uddin FS, Iqbal R, Harford WV, et al. Prone positioning of obese patients for colonoscopy results in shortened cecal intubation times: a randomized trial. *Dig Dis Sci* 2013;58:782-7.
13. Marshall JB. Use of a pediatric colonoscope improves the success of total colonoscopy in selected adult patients. *Gastrointest Endosc* 1996;44:675-8.
14. Nemoto D, Utano K, Endo S, et al. Ultrathin versus pediatric instruments for colonoscopy in older female patients: a randomized trial. *Dig Endosc* 2017;29:168-74.
15. Sofi A, Nawras A, Khan M, et al. Meta-analysis of the performance of ultrathin vs. standard colonoscopes. *Endoscopy* 2017;49:351-8.
16. Morimoto K, Watanabe K, Noguchi A, et al. Clinical impact of ultrathin colonoscopy for Crohn's disease patients with strictures. *J Gastroenterol Hepatol* 2015;30(Suppl 1):66-70.
17. Girotra M, Barakat MT, Huang RJ, et al. When experts fail: short turn radius colonoscope to the rescue? Utility of a novel colonoscope for incomplete colonoscopy due to bowel fixity [abstract]. *Gastrointest Endosc* 2017;85:AB517.
18. McGill SK. Short turn radius colonoscope in an anatomical model: retroflexed withdrawal and detection of hidden polyps. *World J Gastroenterol* 2015;21:593.
19. Othman M, Bradley A, Choudhary A, et al. Variable stiffness colonoscope versus regular adult colonoscope: meta-analysis of randomized controlled trials. *Endoscopy* 2009;41:17-24.
20. Brooker JC, Saunders BP, Shah SG, et al. A new variable stiffness colonoscope makes colonoscopy easier: a randomized controlled trial. *Gut* 2000;46:801-5.
21. Yoshikawa I, Honda H, Nagata K, et al. Variable stiffness colonoscopes are associated with less pain during colonoscopy in unsedated patients. *Am J Gastroenterol* 2002;97:3052-5.
22. Saunders BP, East JE. What are the benefits of the variable-stiffness colonoscope? *Nat Clin Pract Gastroenterol Hepatol* 2008;5:8-9.
23. Keswani RN. Single-balloon colonoscopy versus repeat standard colonoscopy for previous incomplete colonoscopy: a randomized, controlled trial. *Gastrointest Endosc* 2011;73:507-12.
24. Teshima CW, Aktas H, Haringsma J, et al. Single-balloon-assisted colonoscopy in patients with previously failed colonoscopy. *Gastrointest Endosc* 2010;71:1319-23.
25. Friedland S, Kaltenbach T, Soetikno R. Use of the double balloon enteroscope system to complete incomplete colonoscopy. *Tech Gastrointest Endosc* 2008;10:124-7.
26. Suzuki T, Matsushima M, Tsukune Y, et al. Double-balloon endoscopy versus magnet-imaging enhanced colonoscopy for difficult colonoscopies, a randomized study. *Endoscopy* 2012;44:38-42.
27. Hotta K, Katsuki S, Ohata K, et al. A multicenter, prospective trial of total colonoscopy using a short double-balloon endoscope in patients with previous incomplete colonoscopy. *Gastrointest Endosc* 2012;75:813-8.
28. Cirocco WC, Rusin LC. Fluoroscopy. A valuable ally during difficult colonoscopy. *Surg Endosc* 1996;10:1080-4.
29. Eickhoff A, Pickhardt PJ, Hartmann D, et al. Colon anatomy based on CT colonography and fluoroscopy: impact on looping, straightening and ancillary manoeuvres in colonoscopy. *Dig Liver Dis* 2010;42:291-6.
30. Shah SG, Brooker JC, Williams CB, et al. Effect of magnetic endoscope imaging on colonoscopy performance: a randomised controlled trial. *Lancet* 2000;356:1718-22.
31. Shah SG, Saunders BP, Brooker JC, et al. Magnetic imaging of colonoscopy: an audit of looping, accuracy and ancillary maneuvers. *Gastrointest Endosc* 2000;52:1-8.
32. Wehrmann K, Frühmorgen P. Evaluation of a new three-dimensional magnetic imaging system for use during colonoscopy. *Endoscopy* 2002;34:905-8.
33. Shah SG, Brooker JC, Thapar C, et al. Patient pain during colonoscopy: an analysis using real-time magnetic endoscope imaging. *Endoscopy* 2002;34:435-40.
34. Crockett SD, Cirri HO, Kelapure R, et al. Use of an abdominal compression device in colonoscopy: a randomized, sham-controlled trial. *Clin Gastroenterol Hepatol* 2016;14:850-7.
35. Toros AB, Ersoz F, Ozcan O. Does a fitted abdominal corset makes colonoscopy more tolerable? *Dig Endosc* 2012;24:164-7.
36. Trindade A, Mella J, Slattery E, et al. Use of a cap in single-balloon enteroscopy-assisted endoscopic retrograde cholangiography. *Endoscopy* 2014;47:453-6.
37. Morgan J, Thomas K, Lee-Robichaud H, et al. Transparent cap colonoscopy versus standard colonoscopy to improve caecal intubation. *Cochrane Database System Rev* 2012;12:CD008211.
38. Sanchez-Yague A, Kaltenbach T, Yamamoto H, et al. The endoscopic cap that can (with videos). *Gastrointest Endosc* 2012;76:169-78.
39. Kim D-H, Park S-Y, Park C-H, et al. Cap-assisted gastroscope versus cap-assisted colonoscope for examination of difficult sigmoid colons in a nonsedated Asian population: a randomized study. *Gastrointest Endosc* 2014;79:790-7.
40. Ness RM, Gottlieb K, Rex DK, et al. Difficult sigmoid colon intubation: guide wire exchange technique. *Gastrointest Endosc* 1996;44:99-101.
41. Rex DK. Achieving cecal intubation in the very difficult colon. *Gastrointest Endosc* 2008;67:938-44.
42. East JM. Effect of a proprietary intraluminal stiffening wire device on cecal intubation time and rate with used colonoscopes; a randomized, controlled trial. *BMC Res Notes* 2013;6:48.
43. Shah SG, Saunders BP. Aids to insertion: magnetic imaging, variable stiffness, and overtubes. *Gastrointest Endosc Clin North Am* 2005;15:673-86.
44. Friedland S, Soetikno RM. Small caliber overtube-assisted colonoscopy. *World J Gastroenterol* 2007;13:5933-7.
45. Vemulapalli KC, Rex DK. Water immersion simplifies cecal intubation in patients with redundant colons and previous incomplete colonoscopies. *Gastrointest Endosc* 2012;76:812-7.
46. Leung CW, Kaltenbach T, Soetikno R, et al. Water immersion versus standard colonoscopy insertion technique: randomized trial shows promise for minimal sedation. *Endoscopy* 2010;42:557-63.

47. Hsieh Y-H, Lin H-J, Tseng K-C. Limited water infusion decreases pain during minimally sedated colonoscopy. *World J Gastroenterol* 2011;17:2236-40.
48. Radaelli F, Paggi S, Amato A, et al. Warm water infusion versus air insufflation for unsedated colonoscopy: a randomized, controlled trial. *Gastrointest Endosc* 2010;72:701-9.
49. Leung JW, Mann SK, Siao-Salera R, et al. A randomized, controlled comparison of warm water infusion in lieu of air insufflation versus air insufflation for aiding colonoscopy insertion in sedated patients undergoing colorectal cancer screening and surveillance. *Gastrointest Endosc* 2009;70:505-10.
50. Leung FW, Harker JO, Jackson G, et al. A proof-of-principle, prospective, randomized, controlled trial demonstrating improved outcomes in scheduled unsedated colonoscopy by the water method. *Gastrointest Endosc* 2010;72:693-700.
51. Ramirez FC, Leung FW. A head-to-head comparison of the water vs. air method in patients undergoing screening colonoscopy. *J Interv Gastroenterol* 2011;1:130-5.
52. GE Technology Assessment Committee; Maple JT, Banerjee S, Barth BA, et al. Methods of luminal distention for colonoscopy. *Gastrointest Endosc* 2013;77:519-25.
53. Xie Q, Chen B, Liu L, et al. Does the variable-stiffness colonoscope makes colonoscopy easier? A meta-analysis of the efficacy of the variable stiffness colonoscope compared with the standard adult colonoscope. *BMC Gastroenterol* 2012;12:151.
54. Park C-H, Lee W-S, Joo Y-E, et al. Sedation-free colonoscopy using an upper endoscope is tolerable and effective in patients with low body mass index: a prospective randomized study. *Am J Gastroenterol* 2006;101:2504-10.
55. Tan M, Lahiff C, Bassett P, et al. Efficacy of balloon overtube-assisted colonoscopy in patients with incomplete or previous difficult colonoscopies: a meta-analysis. *Clin Gastroenterol Hepatol* 2017;15:1628-30.
56. Yung DE, Koulaouzidis A, Fraser C, et al. Double-balloon colonoscopy for failed conventional colonoscopy: the Edinburgh experience and systematic review of existing data. *Gastrointest Endosc* 2016;84: 878-81.
57. Sulz MC, Frei R, Semadeni G-M, et al. The role of single-balloon colonoscopy for patients with previous incomplete standard colonoscopy: Is it worth doing it? *Surg Endosc* 2016;30:1876-82.
58. Dzeletovic I, Harrison ME, Pasha SF, et al. Comparison of single- versus double-balloon assisted-colonoscopy for colon examination after previous incomplete standard colonoscopy. *Dig Dis Sci* 2012;57:2680-6.
59. Yamada A. Utility of single and double balloon endoscopy in patients with difficult colonoscopy: a randomized controlled trial. *World J Gastroenterol* 2013;19:4732.
60. Hotta K, Katsuki S, Ohata K, et al. Efficacy and safety of endoscopic interventions using the short double-balloon endoscope in patients after incomplete colonoscopy. *Dig Endosc* 2015;27:95-8.
61. Mark-Christensen A, Brandsborg S, Iversen LH. Magnetic endoscopic imaging as an adjuvant to elective colonoscopy: a systematic review and meta-analysis of randomized controlled trials. *Endoscopy* 2015;47:251-61.
62. Chen Y. Magnetic endoscopic imaging vs standard colonoscopy: meta-analysis of randomized controlled trials. *World J Gastroenterol* 2013;19: 7197.
63. Halpern Z, Adler SN, Santo EM. Challenging colonoscopy: safety and effectiveness of a new on-demand balloon device for facilitating complete colonoscopy in challenging patient anatomy [abstract]. *Gastrointest Endosc* 2012;75:AB340-1.
64. Kantsevov SV, Bitner M, Zhang H, et al. Visualization balloon facilitated colonoscopy in 103 consecutive patients with documented difficult or even impossible previous colonoscopy [abstract]. *Gastrointest Endosc* 2017;85:AB263.
65. Chiorean MV, Koch J, Kozarek RA, et al. Effectiveness and safety of a new insufflation-less method for colonoscopy [abstract]. *Gastrointest Endosc* 2015;81:AB380.
66. Westwood DA, Alexakis N, Connor SJ. Transparent cap-assisted colonoscopy versus standard adult colonoscopy. *Dis Colon Rectum* 2012;55:218-25.
67. Ng SC, Tsoi KKF, Hirai HW, et al. The efficacy of cap-assisted colonoscopy in polyp detection and cecal intubation: a meta-analysis of randomized controlled trials. *Am J Gastroenterol* 2012;107: 1165-73.
68. Shida T, Takano S, Kaiho M, et al. Transparent hood attached to a gastroscope: a simple rescue technique for patients with difficult or incomplete colonoscopy. *Endoscopy* 2008;40(Suppl 2):E139.
69. Leung J, Mann S, Siao-Salera R, et al. A randomized, controlled trial to confirm the beneficial effects of the water method on U.S. veterans undergoing colonoscopy with the option of on-demand sedation. *Gastrointest Endosc* 2011;73:103-10.
70. Luo H, Zhang L, Liu X, et al. Water exchange enhanced cecal intubation in potentially difficult colonoscopy. Unsedated patients with prior abdominal or pelvic surgery: a prospective, randomized, controlled trial. *Gastrointest Endosc* 2013;77:767-73.
71. Shergill AK, McQuaid KR, Deleon A, et al. Randomized trial of standard versus magnetic endoscope imaging colonoscopes for unsedated colonoscopy. *Gastrointest Endosc* 2012;75:1031-6.
72. Kondo S, Yamaji Y, Watabe H, et al. A randomized controlled trial evaluating the usefulness of a transparent hood attached to the tip of the colonoscope. *Am J Gastroenterol* 2007;102:75-81.
73. Leung FW. Vital signs and serum electrolyte levels are well preserved after large volume water exchange in the colonic lumen used with the water exchange method. *J Interv Gastroenterol* 2013;3:89.
74. Leung JW, Siao-Salera R, Abramyan O, et al. Impact of water exchange colonoscopy on serum sodium and potassium levels: an observational study. *Dig Dis Sci* 2014;59:653-7.
75. Ramirez FC, Leung FW. The water method for aiding colonoscope insertion: the learning curve of an experienced colonoscopist. *J Interv Gastroenterol* 2011;1:97-101.
76. Tumino E, Sacco R, Bertini M, et al. Endotics system vs colonoscopy for the detection of polyps. *World J Gastroenterol* 2010;16:5452-6.
77. Cosentino F, Tumino E, Passoni GR, et al. Functional evaluation of the endotics system, a new disposable self-propelled robotic colonoscope: in vitro tests and clinical trial. *Int J Artif Organs* 2009;32:517-27.
78. Eickhoff A, Van Dam J, Jakobs R, et al. Computer-assisted colonoscopy (the NeoGuide Endoscopy System): Results of the first human clinical trial ("PACE Study"). *Am J Gastroenterol* 2007;102:261-6.
79. Gluck N, Melhem A, Halpern Z, et al. A novel self-propelled disposable colonoscope is effective for colonoscopy in humans (with video). *Gastrointest Endosc* 2016;83:998-1004.