

## Enhanced ultrasound imaging

*The American Society for Gastrointestinal Endoscopy (ASGE) Technology Committee provides reviews of emerging endoscopic technologies that have an impact on the practice of GI endoscopy. Evidence-based methodology is used, with MEDLINE and PubMed literature searches to identify pertinent clinical studies on the topic. Because many topics have a limited number of peer-reviewed manuscripts, abstracts from scientific meetings are used to supplement the review. The reports focus on the current status of the technologies, areas in need of further research, and barriers to incorporation into the mainstream practice of GI endoscopy.*

*Reports on Emerging Technologies are drafted by one or two members of the ASGE Technology Committee, reviewed and edited by the committee as a whole, and approved by the governing board of the ASGE. These reports are scientific reviews provided solely for educational and informational purposes. Reports on Emerging Technologies are not rules and should not be construed as establishing a legal standard of care or as encouraging, advocating, requiring, or discouraging any particular treatment or payment for such treatment.*

### BACKGROUND

EUS has assumed a primary role in the evaluation of intraluminal and extraluminal pathology. However, even with the addition of tissue sampling via FNA, some limitations exist in the differentiation of benign from malignant processes. Recent innovations in EUS intended to address these limitations include contrast-enhanced EUS (CE-EUS) and EUS elastography.

### EMERGING TECHNOLOGIES

#### Elastography

Elastography is a modality that evaluates tissue stiffness by its response to compression. US waves travel at different speeds through tissues of different stiffness. Compression of tissue changes its mechanical properties and its reflection of US waves (Fig. 1). An abnormal lesion may deform to a lesser degree in response to compression than surrounding normal tissue. For example, malignant tumors

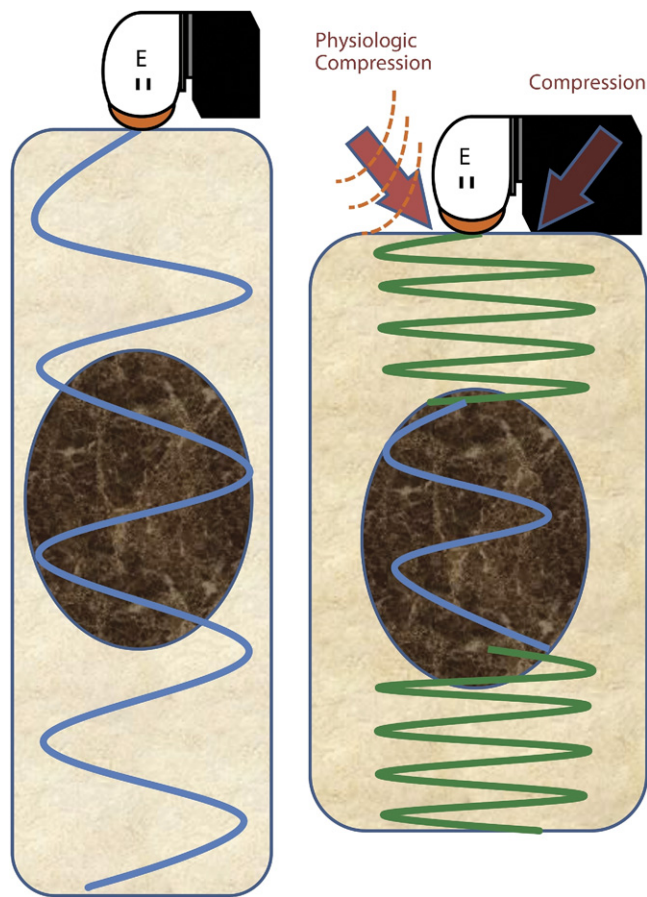
exhibit increased tissue stiffness compared with benign tumors or normal tissue.<sup>1-3</sup> Elastography compares the spatial arrangement of the tissue and the velocity of US waves at rest and after compression.<sup>4-6</sup> When the tissue of a lesion is harder compared with the surrounding normal organ, the echoes will be less distorted than in the surrounding tissues.

Elastography with transcutaneous US has been used in the evaluation of organs such as breast, thyroid, and liver,<sup>7</sup> and recently has become available for use with EUS.<sup>4-6</sup> Developments in software and imaging processing (HV-900; Pentax, Montvale, NJ) allow for measurement of tissue response to both external mechanical stimuli (eg, pushing the endoscope against the esophageal wall) and/or physiologic movement (eg, vascular pulsations). Real-time elastography is performed with standard echoendoscopes (EG-3870UTK linear, EG-3670URK radial, Pentax) and displayed as an overlay of transparent colors over the regular gray-scale B-mode US image. Softer tissue is depicted as red, intermediate areas as green, and stiffer areas as blue. These color differences highlight tissue changes of malignant or fibrotic lesions compared with surrounding normal tissue.

#### Potential applications

Conventional EUS with FNA in the evaluation of solid pancreatic masses is limited by relatively low sensitivity for malignancy.<sup>8-10</sup> In an attempt to improve sensitivity, elastography has been applied in the evaluation of focal pancreatic lesions. Early studies used a color display and/or a relative numerical scoring system (score 1 to 5) to evaluate the stiffness of the tissue. They demonstrated good sensitivity but poor specificity in differentiating between malignant and benign lesions such as inflammatory or fibrotic masses.<sup>11-14</sup> Reported limitations included difficulties with delineation of the margin of lesions and evaluation of larger (>35 mm) or deeper lesions. More recently, a multicenter series of 121 patients reported an 89% accuracy rate.<sup>15</sup> A prospective, single-center study of 130 consecutive patients with pancreatic masses also revealed high accuracy (94%) for prediction of malignancy, with excellent interobserver agreement between the two endosonographers ( $k = 0.772$ ).<sup>16</sup> Disagreement occurred in 8 cases of inflammatory masses and 1 neuroendocrine tumor.

Newer elastography software calculates the strain ratio between a lesion and adjacent softer tissue, allowing for the addition of quantitative measurement to the qualitative



**Figure 1.** The principle of elastography. The tissue is evaluated with US. **A.** At rest, the harder tissue (depicted as the circular marble mass) within the softer organ. **B.** After compression, the harder tissue will be less distorted than the surrounding tissues. The US waves will travel faster through the less-deformed hard mass. E, echoendoscope.

pattern and color recognition. In a single-center study of 86 consecutive patients with solid pancreatic masses, quantitative elastography demonstrated excellent sensitivity (100%) but lower specificity (92%) for malignancy.<sup>17</sup> Another innovation is software that analyzes elastographic images. This was developed to make image interpretation less subjective and to increase the accuracy of differentiation between benign and malignant lesions. This software had good accuracy (89%) in a feasibility study.<sup>18</sup>

Elastographic evaluation of lymph nodes also has been reported.<sup>11,19,20</sup> It performed better than the standard morphologic EUS criteria for malignancy.<sup>5</sup> Other potential applications in gastroenterology include EUS evaluation of focal liver lesions and the postradiotherapy evaluation of rectal cancer.<sup>21,22</sup>

### CE-EUS

CE-EUS consists of injection of contrast medium during standard EUS examination. It uses the altered vascular characteristics of malignancy to enhance visualization compared with surrounding tissues.

Current US contrast agents are composed of a microsphere containing gas bubbles within a shell (microbubbles).<sup>23,24</sup> After intravenous administration, the US contrast medium remains in the vascular space and enhances the visualization of blood vessels, from large vessels and heart chambers to the microcirculation within the pancreatic parenchyma. For the pancreas, an initial macrovascular phase followed by a microvascular phase has been described.<sup>25,26</sup> The contrast reaches maximum intensity in 20 to 30 seconds after injection but may last up to 5 to 10 minutes in the microcirculation.<sup>27</sup>

Microbubble agents available in the US contain perfluoropropane gas microspheres and are marketed as Optison (GE Healthcare, Princeton, NJ), approved in 1997, and Definity (Lantheus Medical Imaging, Billerica, Mass), approved in 2001. In October 2007, the U.S. Food and Drug Administration issued a black box warning and new contraindications for contrast agents containing perfluoropropane because of reports of cardiac ischemia. However, some of these cardiac restrictions were recently eased.<sup>28</sup> Overall, adverse event rates are low (0.6%) and include mainly back pain and headache.<sup>29,30</sup> Hypersensitivity to perfluoropropane is rare (0.014%) but can be severe, including anaphylactoid or anaphylactic reactions.<sup>31</sup>

Color Doppler or power Doppler was the initial EUS mode used for CE-EUS. This resulted in improved imaging compared with standard B-mode, but this had a low sensitivity for microvasculature. The resulting image was blemished with motion artifacts and blooming effect in blood vessels.<sup>32,33</sup> Newer echoendoscopes with wider bandwidth transducers and processors with harmonic imaging software (GF-UE160-AL5, ExPHD detection mode in Aloka Prosound SSD Alpha-10, Olympus) may improve resolution from areas of low blood flow when used with contrast medium.<sup>34</sup>

### Potential applications

Several clinical studies have evaluated CE-EUS with color Doppler or power Doppler. Hypovascularity during contrast enhancement (hypo-enhancing lesion) was typically associated with malignancy and other lesions, such as neuroendocrine tumors, were hypervascular (hyper-enhancing lesion) or isovascular relative to the normal parenchyma.<sup>31,35</sup> Small pancreatic endocrine tumors were more clearly seen with contrast-enhanced color Doppler EUS in a retrospective series of 41 patients with 62 lesions. When compared with pathologic confirmation, EUS with contrast had an excellent sensitivity of 95%.<sup>36</sup>

CE-EUS using harmonic imaging has been used in the evaluation of intra-abdominal lesions of undetermined etiology with high accuracy (97%) for malignancy.<sup>37</sup> Another study of solid pancreatic masses showed excellent sensitivity (96%) and good accuracy (82%) for malignancy for CE-EUS using harmonic imaging mode.<sup>25</sup> A noteworthy finding in this study was the detection of small lesions in seven patients with biliary stents or chronic pancreatitis

that were not initially seen with standard EUS images, leading to an 8% increase in overall diagnostic yield. Two other small studies of pancreaticobiliary malignancy also showed good sensitivity and accuracy.<sup>26,38</sup> A single-center report suggests that the combination of both elastography and CE-EUS may identify patients with focal pancreatic masses that need a more aggressive approach with repeat EUS-FNA or even referral for surgery. In 54 patients with focal pancreatic masses, the combination had a very good positive predictive value (96%) and negative predictive value of 71%.<sup>39</sup>

## AREAS FOR FUTURE RESEARCH

Multicenter prospective studies comparing CE-EUS and elastography to other diagnostic techniques are needed. Specifically, the role of these technologies in differentiating between benign and malignant pathology needs to be further clarified. Validation and cost-effectiveness studies also are warranted. Additionally, prospective data may help establish cost-effectiveness. Newer microbubbles that specifically target certain types of malignancy on a molecular basis are being developed.<sup>40</sup> The efficacy and safety of these target-specific agents await further study.

## SUMMARY

Elastography and CE-EUS are new technologies that may improve the real-time evaluation of extraluminal lesions. Further studies are needed to define their role.

## DISCLOSURE

*No financial relationships relevant to this publication were disclosed.*

*Abbreviations: ASGE, American Society for Gastrointestinal Endoscopy; CE-EUS, contrast-enhanced EUS.*

## REFERENCES

- Ophir J, Caspedes I, Ponnekanti H, et al. Elastography: a quantitative method for imaging the elasticity of biological tissue. *Ultrason Imaging* 1991;13:111-34.
- Krouskop TA, Wheeler TM, Kallel F, et al. Elastic moduli of breast and prostate tissues under compression. *Ultrason Imaging* 1998;20:260-74.
- Ophir J, Alam SK, Garra B, et al. Elastography: ultrasonic estimation and imaging of the elastic properties of tissues. *Proc Inst Mech Eng H* 1999; 213:203-33.
- Giovannini M. Contrast-enhanced endoscopic ultrasound and elastosonoendoscopy. *Best Pract Res Clin Gastroenterol* 2009;23:767-79.
- Jacobson BC. Pressed for an answer: has elastography finally come to EUS? *Gastrointest Endosc* 2007;66:301-3.
- Hirooka Y, Itoh A, Kawashima H, et al. Diagnosis of pancreatic disorders using contrast-enhanced endoscopic ultrasonography and endoscopic elastography. *Clin Gastroenterol Hepatol* 2009;7:563-567.
- Garra, BS. Imaging and estimation of tissue elasticity by ultrasound. [Review] *Ultrasound Q* 2007;23:255-68.
- Varadarajulu S, Tamhane A, Eloubeidi MA. Yield of EUS-guided FNA of pancreatic masses in the presence or the absence of chronic pancreatitis. *Gastrointest Endosc* 2005;62:728-36.
- Fritscher-Ravens A, Brand L, Knofel WT, et al. Comparison of endoscopic ultrasound-guided fine needle aspiration for focal pancreatic lesions in patients with normal parenchyma and chronic pancreatitis. *Am J Gastroenterol* 2002;97:2768-75.
- Savides TJ, Donohue M, Hunt G, et al. EUS-guided FNA diagnostic yield of malignancy in solid pancreatic masses: a benchmark for quality performance measurement. *Gastrointest Endosc* 2007;66:277-82.
- Giovannini M, Hookey LC, Bories E, et al. Endoscopic ultrasound elastography: the first step towards virtual biopsy? Preliminary results in 49 patients. *Endoscopy* 2006;38:344-8.
- Săftoiu A, Vilman P. Endoscopic ultrasound elastography: a new imaging technique for the visualization of tissue elasticity distribution. *J Gastrointest Liver Dis* 2006;15:161-5.
- Janssen J, Dietrich CF, Will U, et al. Endosonographic elastography in the diagnosis of mediastinal lymph nodes. *Endoscopy* 2007;39:952-7.
- Hirche TO, Ignee A, Barreiros AP, et al. Indications and limitations of endoscopic ultrasound elastography for evaluation of focal pancreatic lesions. *Endoscopy* 2008;40:910-7.
- Giovannini M, Thomas B, Erwan B, et al. Endoscopic ultrasound elastography for evaluation of lymph nodes and pancreatic masses: a multicenter study. *World J Gastroenterol* 2009;15:1587-93.
- Iglesias-Garcia J, Larino-Noia J, Abdulkader I, et al. EUS elastography for the characterization of solid pancreatic masses. *Gastrointest Endosc* 2009;70:1101-8.
- Iglesias-Garcia J, Larino-Noia J, Abdulkader I, et al. Quantitative endoscopic ultrasound elastography: an accurate method for the differentiation of solid pancreatic masses. *Gastroenterology* 2010;139:1172-80.
- Săftoiu A, Vilman P, Gorunescu F, et al. Neural network analysis of dynamic sequences of EUS elastography used for the differential diagnosis of chronic pancreatitis and pancreatic cancer. *Gastrointest Endosc* 2008;68:1086-94.
- Săftoiu A, Vilman P, Ciurea T, et al. Dynamic analysis of endoscopic ultrasound (EUS) elastography used for the differentiation of benign and malignant lymph nodes. *Gastrointest Endosc* 2007;66:291-300.
- Janssen J, Dietrich CF, Will U, et al. Endosonographic elastography in the diagnosis of mediastinal lymph nodes. *Endoscopy* 2007;39:952-7.
- Rustemovic N, Hrstic I, Opacic M, et al. EUS elastography in the diagnosis of focal liver lesions. *Gastrointest Endosc* 2007;66:823-4.
- Mezzi G, Arcidiacono PG, Carrara S, et al. Elastosonography in malignant rectal disease: preliminary data. *Endoscopy* 2007;39:375.
- Claudon M, Cosgrove D, Albrecht T, et al. Guidelines and good clinical practice recommendations for contrast enhanced ultrasound (CEUS)—update 2008. *Ultraschall Med* 2008;29:28-44.
- Feinstein SB, Coll B, Staub D, et al. Contrast enhanced ultrasound imaging. *J Nucl Cardiol* 2010;17:106-15.
- Fusaroli P, Spada A, Mancino MG, et al. Contrast harmonic endoscopic ultrasound improves accuracy in diagnosis of solid pancreatic masses. *Clin Gastroenterol Hepatol* 2010;8:629-34.
- Napoleon B, Alvarez-Sanchez MV, Gincoul R, et al. Contrast-enhanced harmonic endoscopic ultrasound in solid lesions of the pancreas: results of a pilot study. *Endoscopy* 2010;42:564-70.
- D'Onofrio M, Zamboni G, Tognolini M, et al. Ultrasonography of the pancreas: 4-contrast-enhanced imaging. *Abdom Imaging* 2007;32: 171-81.
- Information for healthcare professionals: Micro-bubble contrast agents (marketed as Definity (perflutren lipid microsphere) injectable suspension and Optison (perflutren protein-type A microspheres for injection). <http://www.fda.gov/Drugs/DrugSafety/PostmarketDrugSafetyInformationforPatientsandProviders/ucm110260.htm>. Accessed March 2, 2011.
- Agelli C, Giannopoulos G, Roussakis G, et al. Safety of myocardial flash-contrast echocardiography in combination with dobutamine stress testing for the detection of ischaemia in 5250 studies. *Heart* 2008;94: 1571-7.

30. Khawaja OA, Shaikh KA, Al-Mallah MH. Meta-analysis of adverse cardiovascular events associated with echocardiographic contrast agents. *Am J Cardiol* 2010;106:742-7.
31. Wilson SR, Burns PN. Microbubble-enhanced US in body imaging: what role? *Radiology* 2010;257:24-39.
32. Dietrich CF, Ignee A, Braden B, et al. Improved differentiation of pancreatic tumors using contrast-enhanced endoscopic ultrasound. *Clin Gastroenterol Hepatol* 2008;6:590-7.
33. Hocke M, Schulze E, Gottschalk P, et al. Contrast-enhanced endoscopic ultrasound in discrimination between focal pancreatitis and pancreatic cancer. *World J Gastroenterol* 2006;12:246-50.
34. Dietrich CF. Contrast-enhanced low mechanical index endoscopic ultrasound (CELMI-EUS). *Endoscopy* 2009;41:E43-E44.
35. Rickes S, Monkemuller K, Malfertheiner P. Contrast-enhanced ultrasound in the diagnosis of pancreatic tumors. *J Pancreas* 2006;7:584-92.
36. Ishikawa T, Itoh A, Kawashima H, et al. Usefulness of EUS combined with contrast-enhancement in the differential diagnosis of malignant versus benign and preoperative localization of pancreatic endocrine tumors. *Gastrointest Endosc* 2010;71:951-9.
37. Xia Y, Kitano M, Kudo M, et al. Characterization of intra-abdominal lesions of undetermined origin by contrast-enhanced harmonic EUS (with videos). *Gastrointest Endosc* 2010;72:637-42.
38. Imazu H, Uchiyama Y, Matsunaga K, et al. Contrast-enhanced harmonic EUS with novel ultrasonographic contrast (Sonazoid) in the preoperative T-staging for pancreaticobiliary malignancies. *Scand J Gastroenterol* 2010;45:732-8.
39. Săftoiu A, Iordache SA, Gheonea DI, et al. Combined contrast-enhanced power Doppler and real-time sonoelastography performed during EUS, used in the differential diagnosis of focal pancreatic masses (with videos). *Gastrointest Endosc* 2010;72:739-47.
40. Kiessling F. Science to practice: the dawn of molecular US imaging for clinical cancer imaging. *Radiology* 2010;256:331-3.

---

Prepared by:  
ASGE Technology Committee  
Subhas Banerjee, MD  
Bradley A. Barth, MD, NASPGHAN Representative  
David J. Desilets, MD  
Vivek Kaul, MD  
Sripathi R. Kethu, MD  
Marcos C. Pedrosa, MD  
Patrick R. Pfau, MD  
Jeffrey L. Tokar, MD  
Shyam Varadarajulu, MD  
Amy Wang, MD  
Louis-Michel Wong Kee Song, MD  
Sarah A. Rodriguez, MD, Committee Chair  
This document is a product of the ASGE Technology Committee. This document was reviewed and approved by the governing board of the American Society for Gastrointestinal Endoscopy.

---

### **GIE on Facebook**

GIE now has a Facebook page. Fans will receive news, updates, and links to author interviews, podcasts, articles, and tables of contents. Search on Facebook for “GIE: Gastrointestinal Endoscopy” and become a fan.